Airway-centered Interstitial Fibrosis

A Distinct Form of Aggressive Diffuse Lung Disease

Andrew Churg, MD, Jeffrey Myers, MD,† Teresa Suarez, MD,‡ Miguel Gaxiola, MD,‡ Andrea Estrada, MD,‡ Mayra Mejia, MD,‡ and Moises Selman, MD‡*

Abstract: We describe 12 patients with a form of interstitial lung disease characterized pathologically by small airway-centered interstitial fibrosis and metaplastic bronchiolar epithelium extending around and often linking fibrotic and sometimes heavily muscularized bronchioles. Clinically, patients presented with chronic cough and progressive dyspnea. One was a current light smoker and two were ex-smokers. In 8 patients, a history of possible inhalational exposures, including wood smoke, birds, cotton, pasture, chalk dust, agrochemical compounds, and cocaine use, was elicited. Pulmonary function tests showed moderate to severe physiologic abnormalities, in most instances indicating a restrictive lung disease with decreased peripheral flow rates. Chest radiographs revealed predominantly diffuse reticulonodular infiltrates in the central lung fields, with thickening of the bronchial walls and decreased lung volumes. Chest computed tomography demonstrated peribronchovascular fibrosis and interstitial thickening. Bronchoalveolar lavage showed a mild increase in lymphocytes in 4 subjects. Patients were treated with corticosteroids and bronchodilators. Follow-up data were available in 10 patients. In 5 patients, the disease progressed and 4 of them died. Two patients remained stable and 3 improved or healed. We propose that these findings represent a distinct airway-centered disease that mostly behaves as an interstitial lung disease and may exhibit a poor outcome.

Key Words: bronchiolitis, interstitial lung disease, small airway disease, fibrosis

(*Am J Surg Pathol* 2004;28:62–68)

The idiopathic interstitial pneumonias consist of a set of diseases of unknown etiology characterized pathologically by a variable combination of interstitial fibrosis and inflammation with, in some instances, airspace macrophages or granulation tissue.[1,5] As a general rule, the inflammatory and fibrotic changes are widespread and variably affect bronchovascular bundles, alveolar septa, interlobular connective tissue septa, and occasionally visceral pleura. Most of these lesions demonstrate either a homogeneous distribution within the lobule or a tendency to peripheral accentuation, as in usual interstitial pneumonia. Among the idiopathic interstitial pneumonias, respiratory bronchiolitis-associated interstitial lung disease (RBILD) stands alone as a form of exquisitely bronchiolocentric injury associated with a syndrome of diffuse interstitial lung disease.

Yousem and Dacic[17] recently reported 10 patients with an entity they labeled idiopathic bronchiolocentric interstitial pneumonia. Lung biopsies from theses cases showed a distinctive pattern of interstitial fibrosis extending around the bronchioles, often with bronchiolar metaplasia of the epithelium overlying the fibrotic foci. The etiology of these lesions was unclear, but the authors suggested that they might represent a form of hypersensitivity pneumonia.

In this paper, we describe a series of patients with clinical, functional, and radiologic features of unexplained diffuse interstitial lung disease and a morphologic pattern of bronchiolocentric interstitial fibrosis somewhat similar to that reported by Yousem and Dacic.[17] However, our patients differed in having radiographic evidence of fibrosis around large airways and microscopic evidence of fibrosis around the small airways, suggesting that they have a form of primary airway-centered disease that also has a component of interstitial fibrosis.

METHODS

Study Population

Twelve patients with a distinctive histopathologic picture consisting of scarring and distortion of the bronchioles with interstitial fibrosis extending away from the affected airways were identified in a review of a series of patients with clinical interstitial lung disease from the National Institute of Respiratory Diseases in Mexico City. The pathology specimens were reviewed by two of us (A.C. and J.M.) without knowledge of the clinical details.

The records of these 12 patients, including smoking and environmental exposure history, respiratory function tests,

From the *Department of Pathology, University of British Columbia, Vancouver, British Columbia, Canada; †Department of Pathology, Mayo Clinic, Rochester, Minnesota; and ‡Instituto Nacional de Enfermedades Respiratorias, México City, México.

Reprints: Moisés Selman, MD, Instituto Nacional de Enfermedades Respiratorias, Tlalpan 4502; Col. Sección XVI, México DF, CP 14080, México (e-mail: mselman@sni.conacyt.mx).

Copyright © 2003 by Lippincott Williams & Wilkins

Copyright © Lippincott Williams & Wilkins. Unauthorized reproduction of this article is prohibited.

chest radiographs, chest computed tomography (CT, 5 patients), and bronchoalveolar lavage (7 patients), were reevaluated. Patients were followed from 1 to 10 years after diagnosis (mean 2.9 ± 2.6 years), and outcome was classified at last follow-up as resolved (disappearance of symptoms and normalization of the respiratory function tests), improved (higher 10% increase in forced vital capacity [FVC] plus higher 4 mm Hg increase in PaO_2), stable, worse (higher 10% decrease in FVC plus higher 4 mm Hg decrease in PaO_2), or dead of disease.

RESULTS

Histopathology

At low magnification, the key finding was a distinctive pattern of airway-centered interstitial fibrosis centered on membranous and respiratory bronchioles (Figs. 1–4). The bronchioles themselves were often narrowed and distorted (Figs. 1, 4) but were never overtly obstructed by either granulation tissue plugs or dense fibrosis. In some cases, subepithelial fibrosis was present in the bronchiolar wall, but more commonly the bronchiolar wall was greatly thickened by adventitial fibrous tissue; and in some instances, there was marked muscle hyperplasia (Figs. 1, 2). Although the fibrosing process primarily involved and extended away from the respiratory bronchioles; in many instances, the more proximal membranous bronchioles were abnormal as well, with increased peribronchiolar fibrous tissue (Figs. 2, 3) and sometimes increased bronchiolar muscle (Fig. 2) and occasionally a chronic inflammatory infiltrate in the airway wall.

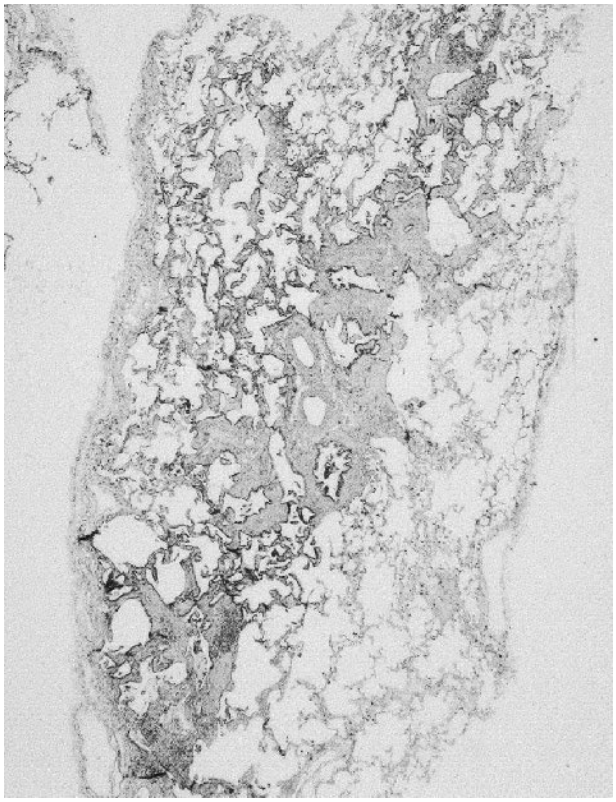

FIGURE 1. Low power view showing the typical combination of fibrosis around the small airways and interstitial fibrosis spreading away from the airways. Note the distortion of the lumens of some of the bronchioles caused by the peribronchiolar fibrous tissue.

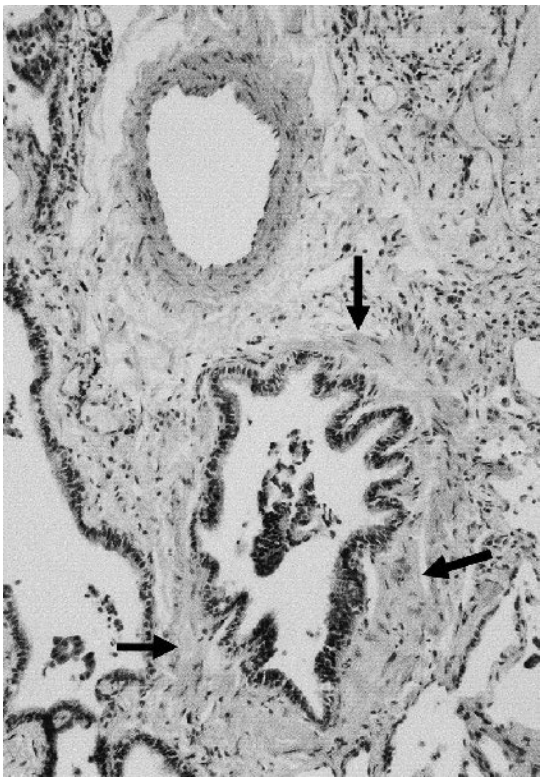

FIGURE 2. Higher power view of the biopsy shown in Figure 1. Note the extensive fibrous tissue around the membranous bronchiole and small arterial branch, and the hyperplastic muscle in the wall of the bronchiole (arrows).

Variable degrees of interstitial fibrosis extended away from the affected airways, and in many instances there was prominent bronchiolar metaplasia overlying the fibrotic alveolar walls (Figs. 1, 3, 5). In some cases, the fibrosing process appeared to link affected bronchioles (Fig. 1); in others, the metaplastic bronchiolar epithelium disappeared, but linear interstitial fibrosis extended considerable distances away from the airway. Interstitial inflammation was sparse in most cases but, when present, was characterized by small numbers of lymphocytes and plasma cells. The airspaces generally contained no or only small numbers of macrophages. Honeycombing was not present in the biopsy samples, and neither bronchiectasis nor bronchiolectasis was observed in the tissues. In some foci, the fibrosing process extended to the pleura and the pleura was often fibrotic as well (Figs. 1, 3, 4).

© 2003 Lippincott Williams & Wilkins

Copyright © Lippincott Williams & Wilkins. Unauthorized reproduction of this article is prohibited.

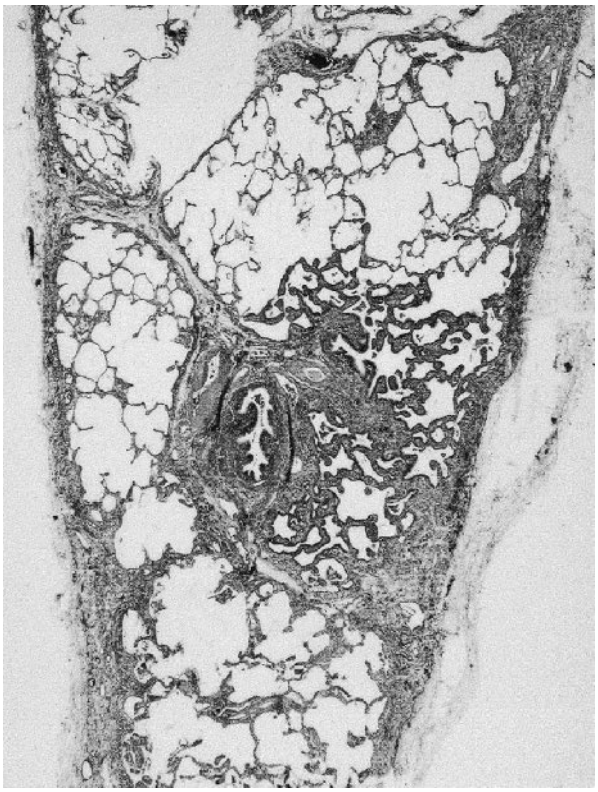

FIGURE 3. Low power view of another case showing interstitial fibrosis spreading around a membranous bronchiole. Note that the pleura is also fibrotic.

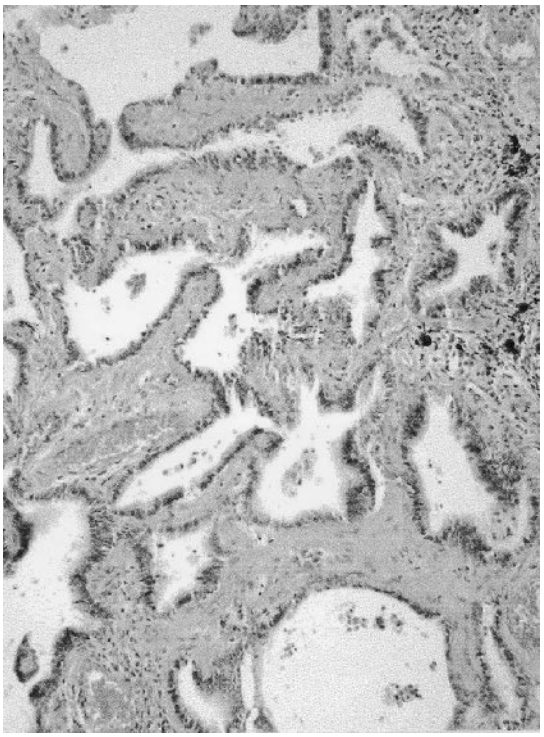

FIGURE 5. High power view showing diffuse, fairly paucicellular, interstitial fibrosis, with overlying metaplastic bronchiolar epithelium.

Demographic and Clinical Data

All patients presented with chronic cough and slowly progressive dyspnea, usually of more than 1 year in duration. There was a 2:1 female predominance, and the disease occurred usually between the ages of 40 and 65 years (Table 1). Respiratory function tests showed a decreased FVC and forced expiratory volume in 1 second (FEV_1). However, FEV_1/FVC ratio was over 80% in 10 of 12 patients, suggesting a restrictive pattern (Table 1). Moreover, the residual volume was decreased or normal in all but two of the patients in which this test was performed. Peripheral flow rates were generally low. Almost all patients had some degree of respiratory insufficiency when first seen, with variable degrees of hypoxemia, and occasionally, with CO_2 retention.

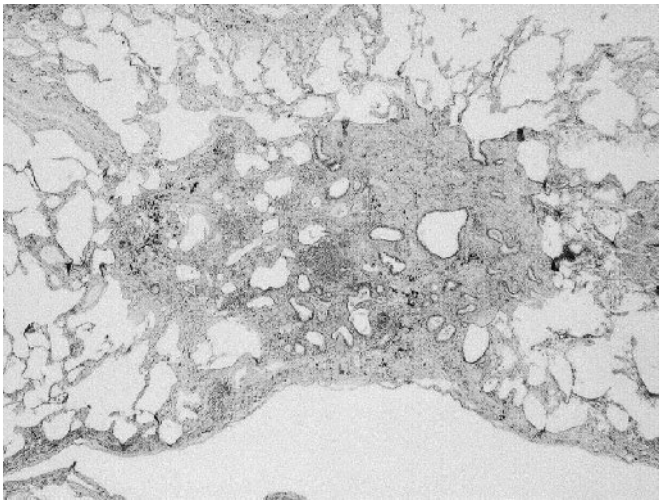

FIGURE 4. Low power view showing a slightly different pattern of extensive fibrosis around a bronchiole with spread of fibrosis into the parenchyma.

Bronchoalveolar lavage was performed in 7 patients without remarkable findings. In 4 patients, a mild to moderate increase of lymphocytes was revealed (Table 1). In addition, bronchoalveolar lavage from 4 of the 7 patients showed from 1% to 4% eosinophils.

Chest radiographs were available for all patients and were always abnormal. The predominant pattern was diffuse reticulonodular infiltrates with central predominance, thickening of the bronchial walls, and small central ring shadows. Small lung fields were observed in 10 patients (Fig. 6). CT scans were available in 5 patients. The main abnormality was peribronchovascular interstitial thickening and traction bronchiectasis with thickened airway walls and surrounding fibrosis (Fig. 7A). Conglomerate fibrotic masses were present adjacent to central airways in some patients. Bronchioloectasis

© 2003 Lippincott Williams & Wilkins

Copyright © Lippincott Williams & Wilkins. Unauthorized reproduction of this article is prohibited.

TABLE 1. Demographic Characteristics of the Patient Group

Patient No.	Gender	Age (yr)	FVC (%)	FEV_1 (%)	FEV_1/FVC	FEF (25–75)	RV	PaO_2*	$PaCO_2$†	BAL Macrophages	BAL Lymphocytes	BAL Neutrophils	BAL Eosinophils
1	M	23	34	37	87	25		62	31				
2	F	47	50	53	80	45		63	26	78	21	1	0
3	F	62	69	55	67	55	140	65	25				
4	F	57	37	41	91	60	84	45	30				
5	F	55	73	74	93	91	78	53	36				
6	M	69	33	32	76	24	92	48	33	63	33	0	4
7	F	45	45	48	84	48		50	30				
8	F	64	57	65	85	51	90	42	35	84	15	0	1
9	F	38	30	33	95	39	81	57	36	61	38	0	1
10	M	66	51	57	86	60	46	48	36	88	12	0	0
11	M	67	57	62	85	58	46	46	39	79	21	0	0
12	F	49	75	79	90	57	186	53	36	93	6	0	1
Mean		54	51	53	85	51	94	53	33	78	21	0	1
SD		13.8	15.8	15.5	7.8	17.7	44.3	7.6	4.4	12.1	11.4	0.4	1.4

FVC, forced vital capacity, percent of predicted; FEV_1, forced expiratory volume in 1 second, percent of predicted; BAL, bronchoalveolar lavage.
*Normal values for Mexico City (2240 m altitude) = 67 ± 3 mm Hg.
†Normal values for Mexico City = 30 ± 3 mm Hg.

and/or honeycombing were present in three patients (Figs. 7B). Only small areas of ground glass attenuation were seen.

Smoking or Environmental/Occupational Exposure

Eight patients had various environmental or occupational exposures that may have been linked to their respiratory syndromes (Table 2). Two of them had birds at home for several years, including the time period when they first noticed respiratory symptoms. These two patients had had other exposures in the past. One of them used an oil stove for cooking for many years, and the other used to work in a cotton (textile) factory. Two patients were exposed for many years to wood smoke, a known cause of chronic bronchitis.[12] An additional patient used to inhale cocaine and was also a current, although minimal (1.5 packs/year), cigarette smoker. One patient was a teacher with a history of exposure to chalk dust for many years; she continued to be exposed at the time of presentation. Of note, she developed rheumatoid arthritis 8 years after the lung biopsy. Two patients were former light (1.25 and 5.25 packs/year) cigarette smokers. One of these latter two patients was also a gardener who was exposed to different agrochemical compounds, and the other was an agricultural worker exposed to dust from pastures. In 4 patients, no significant exposures were identified, although all 4 resided for many years in Mexico City, a region of high air pollution. Two additional patients had also lived in the Mexico City metropolitan area, while the other 6 lived in other regions of Mexico.

Follow-up and Outcome

The first four patients who were seen (patient nos. 1–4 in Tables 1, 2) were treated with prednisone for at least for 1 year, starting with 1 mg/kg per day for 1 month followed by progressive reduction toward maintenance levels of 5 to 15 mg/day. The subsequent 8 patients were treated with a short course of prednisone (3 months), initiating with 0.5 mg/kg per day, followed by inhaled corticosteroids and inhaled bronchodilators for a variable time, but usually for at least one year. In 5 patients, the disease progressed despite treatment, and 4 of them died (1, 3, 3, and 10 years after diagnosis). Two patients remained stable, 3 improved or healed, while 1 was lost during early follow-up and 1 was only recently diagnosed. Four of 5 patients who worsened (patient no. 8) or died (patient nos. 4, 6, and 11) had more severe functional impairment at the time of diagnosis (Table 1).

DISCUSSION

In this paper, we have presented 12 patients with clinical findings of an interstitial lung disease of restrictive type, but a histologic picture that combines a largely fibrotic bronchiolar disease with a variable degree of bronchiolocentric interstitial fibrosis. Because the CT scans show that there is considerable fibrosis around the larger airways as well, we propose that this lesion be called airway-centered interstitial fibrosis (ACIF).

Whether ACIF is primarily a bronchitis/bronchiolitis or an alveolar process that secondarily affects the airways is unclear. It should be noted that we are using bronchiolitis here in

© 2003 Lippincott Williams & Wilkins

Copyright © Lippincott Williams & Wilkins. Unauthorized reproduction of this article is prohibited.

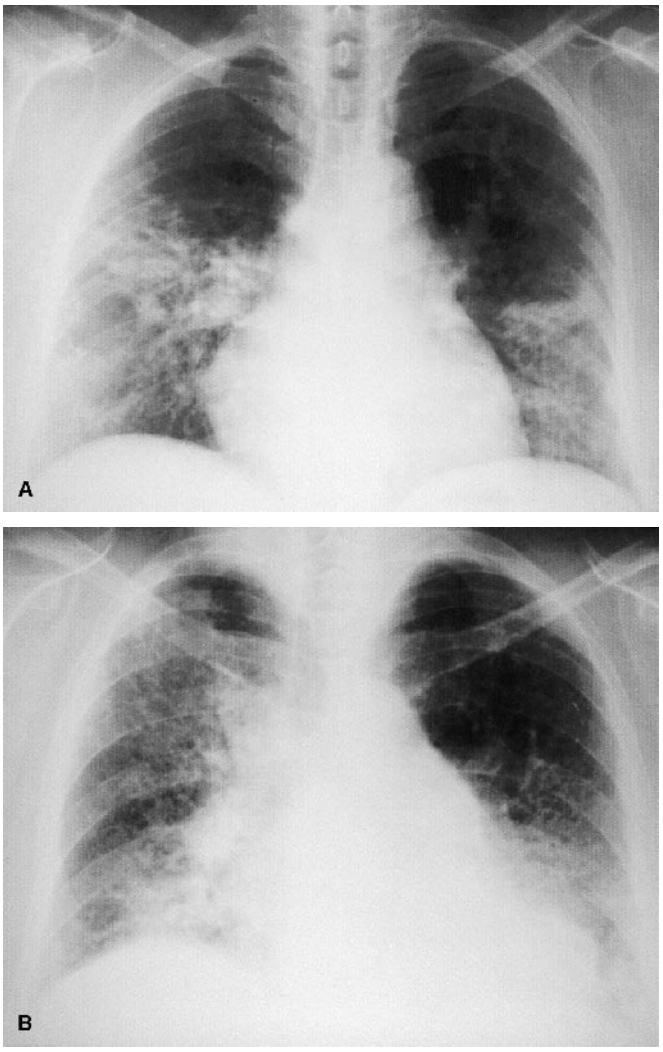

FIGURE 6. A: Chest radiograph corresponding to the same patient described in Figure 3, illustrating reticular infiltrate, central ring shadows, shortening of the lung fields, and images compatible with pulmonary arterial hypertension. **B:** Chest x-ray from a patient with less severe disease and preserved lung volumes.

the broadest sense of the term since the lesions as seen at biopsy are not overtly inflammatory in most cases; rather, the small airways show considerable peri-airway fibrosis and increased muscle, both of which may be the residue of an inflammatory reaction reaction that is no longer present (the same naming convention applies to "constrictive bronchiolitis," see below). Moreover, the apparent airway centricity to the process and the quite variable degrees of interstitial fibrosis suggest that the airway lesions are the earliest manifestation of the disease. This conclusion is made with caution because the CT scans suggest that the disease process is often more severe than is reflected in the biopsies, probably because the lesions show a central rather than a peripheral distribution within the lung, and the worst disease may be missed on biopsy. On the other hand, the CT scans do consistently show scarring around the airways, even the larger airways, again supporting the idea that ACIF is an airway-centered disease that extends into the interstitium.

Relatively few diseases show a combination of an interstitial process affecting the alveolar walls and bronchiolitis. The most notable in this context is hypersensitivity pneumonitis (HP). In most cases of HP, there is a patchy chronic interstitial inflammatory infiltrate with some degree of accentuation around the small airways, but careful examination shows

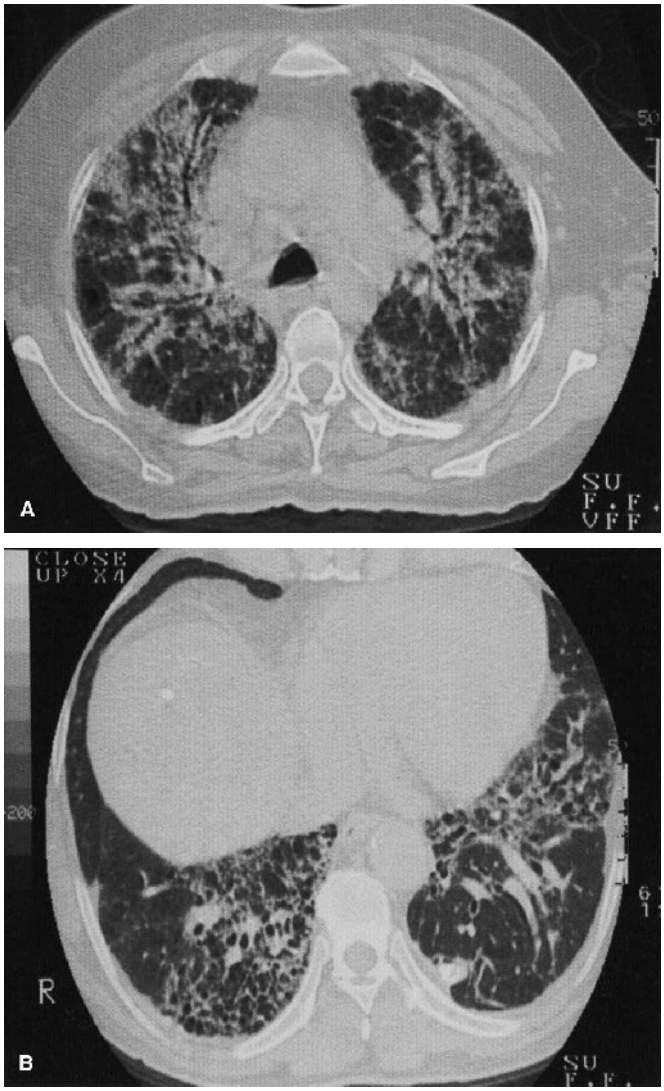

FIGURE 7. A: Lung CT scan of the same patient presented in Figures 1 and 2. There is peribronchovascular interstitial thickening and traction bronchiectasis with bronchial walls thickened surrounding fibrosis. There is also focal ground glass attenuation. **B:** CT scan showing fibrous tissue around bronchi, bronchioloectasis, and some peripheral images suggestive of honeycombing in the right lung.

© 2003 Lippincott Williams & Wilkins

Copyright © Lippincott Williams & Wilkins. Unauthorized reproduction of this article is prohibited.

TABLE 2. Exposure to Noxious Agents, Therapy, and Outcome

Patient No.	Type of Exposure	Treatment	Outcome
1	No exposure	Prednisone	Healed
2	Teacher exposed to chalk dust until the beginning of symptoms; she developed rheumatoid arthritis 8 years after biopsy	Prednisone	Died (10 years)
3	Wood-smoke, exposed at the beginning of symptoms; pigeons during 3 years until 10 years before the beginning of symptoms	Prednisone	Improved
4	Pigeons, exposed at the beginning of symptoms; cotton dusts during 10 years until 12 years before the first consult	Prednisone	Died (3 years)
5	No exposure	Inhaled corticosteroids*	Stable
6	No exposure	Inhaled corticosteroids*	Died (1 year)
7	No exposure	Inhaled corticosteroids*	Unknown
8	Pigeons, exposed at the beginning of symptoms; oil smoke, exposed until 15 years before the first consult.	Inhaled corticosteroids*	Worsened
9	Wood-smoke, exposed at the beginning of symptoms; temporally exposed to pasture	Inhaled corticosteroids*	Improved
10	Pasture, exposed at the beginning of symptoms; former smoker (5.25 pack/year) until 1 year before the beginning of symptoms	Inhaled corticosteroids*	Recent diagnosis
11	Gardener exposed to agrochemical compounds until the beginning of symptoms; former smoker (1.25 pack/years) until 6 years before the beginning of symptoms	Inhaled corticosteroids*	Died (3 years)
12	Cocaine 1–2 years, probably until 1 year before the beginning of symptoms; current smoker (1.5 pack/year)	Inhaled corticosteroids*	Stable

*Prednisone for 3 months followed by inhaled corticosteroids.

that in fact there is often a true bronchiolitis and that this correlates in terms of severity with the degree of interstitial inflammation.[11] The bronchiolocentric inflammatory infiltrate includes poorly formed granulomas in the majority of patients. However, our cases lacked the histologic features of interstitial pneumonia and granulomatous features typical of HP, and interstitial fibrosis in HP is not associated with the type of small airway scarring or with the peculiar pattern of bronchiolar metaplasia seen in our cases patients.

Our cases also lack the clinical and radiologic findings expected in HP. In most cases of HP, CT scans show a combination of ground glass opacities, poorly defined centrilobular micronodules, and air trapping with a mosaic pattern of attenuation,[4] features not seen in the present cases. Only a few of our cases had potential antigenic exposures, and in the two patients with birds at home specific anti-avian antibodies were negative, a situation that is unusual in typical pigeon breeder's disease.[13] Lastly, bronchoalveolar lavage lymphocytosis is usually >40% in HP, and this was not observed in our patients. Therefore, we do not believe that our cases represent a variant of HP.

RBILD is another entity that combines bronchiolar disease with a clinical syndrome resembling other diffuse interstitial lung diseases.[10] RBILD differs considerably from the present cases. Almost all reported patients with RBILD are smokers, whereas only 3 of our 12 cases were ever smokers, and in all instances their total pack-years smoked was very low. RBILD typically shows centrilobular nodules and ground glass opacities on CT scan, although some cases show bronchial wall thickening and peripheral ring shadows.[6,7] Morphologically, RBILD shows much milder airway and interstitial changes than we observed and is always distinguished by the presence of pigmented ("smoker's") macrophages, but these characteristic cells laden with brown or dark pigmented cytoplasmic granules were not identified in our material. As well, RBILD usually responds to steroid therapy or even to cessation of smoking, as opposed to the rather variable response to therapy seen in the present set of patients.

The linear and rather homogeneous appearance of the fibrosing process in ACIF raises a question of whether these lesions could be included in the spectrum of nonspecific interstitial pneumonia. However, nonspecific interstitial pneumonia in general does not show airway centricity[15] and, equally important, nonspecific interstitial pneumonia does not have radiographic evidence of fibrosis surrounding the larger airways.

Constrictive bronchiolitis (CBO), also referred to as obliterative bronchiolitis, shows perhaps the greatest degree of morphologic overlap with the features described in our patients. Pathologically, CBO shows thickened airway walls with a variable mixture of subepithelial fibrosis and muscle hyperplasia. Adventitial fibrosis can be present as well. Typically, in CBO there is either luminal obliteration or clear lumi-

© 2003 Lippincott Williams & Wilkins

Copyright © Lippincott Williams & Wilkins. Unauthorized reproduction of this article is prohibited.

nal narrowing.[7,8] Occasional examples of CBO with some degree of extension of the fibrosing process into the surrounding interstitium, accompanied by bronchiolar metaplasia of the overlying epithelium, have been reported,[7] but the process has generally been mild and very focal. Although the histologic findings in CBO do show some overlap with the cases we describe here, the radiographic findings in our patients are not at all typical of CBO, which usually shows hyperinflation or increased bronchovascular markings. Abnormal small airway tests, such as those we observed, are common in a variety of forms of interstitial lung disease including HP, sarcoidosis, and even ideopathic pulmonary fibrosis (IPF),[3,9,11,14] but most cases of CBO show clinically significant airflow limitation or gas trapping[8] as opposed to the nearly uniform pattern of restriction seen in our patients.

Another form of predominantly centrilobular scarring has been described by De Carvalho et al.[2] These patients had very dense fibrosis that was confined to the centrilobular region and did not spread in the fashion seen our patients; in addition, the airways had necrotic epithelium in almost all their cases. The authors suggested that this process was secondary to aspiration. We did not observe necrotic epithelium, aspirated foreign material, or an acute inflammatory process in any of our cases, and we do not believe that our lesions are related to aspiration.

The histologic findings in our patients are similar in some respects to those recently described by Yousem and Dacic[17] as "idiopathic bronchiolocentric interstitial pneumonia." In both series, there is interstitial inflammation and fibrosis in a peribronchiolar distribution, often with bronchiolar metaplasia. Our patients differ mainly in the presence of prominent radiographic changes involving the airways and in the consistent histologic evidence of quite marked peribronchial fibrosis and increased bronchial muscle. This contrasts with the lack of both large and small airway disease on high resolution CT scans, and the apparently minimal morphologic small airway abnormalities in the 10 patients described by Yousem and Dacic.[17] Similarities include a predilection for women, evidence of restriction and impaired gas exchange on pulmonary function studies, and an aggressive course in some patients; indeed, 33% of the patients reported by Yousem and Dacic died of their disease.[17] Yousem and Dacic proposed that at least some of their patients may have had an unusual form of hypersensitivity pneumonitis (HP), but, as noted, we were unable to find any convincing support for a diagnosis of HP in our patients. Lesions similar to those described in our patients have also been observed by others but without systematic analysis. For example, Travis et al[16] illustrate what may be a very mild variant of this lesion and comment that such patients may have clinical evidence of interstitial lung.

In summary, we describe 12 patients who do not fit into any known category of airways or interstitial lung disease and who appear to illustrate a distinct pattern of airway-centered fibrosis with associated restrictive pulmonary function. Despite the prominent airway involvement, this disorder mostly behaves as an interstitial lung disease. Most of the idiopathic interstitial pneumonias represent reaction patterns with a variety of etiologies. Whether ACIF is a unique and specific disease or, similar to the idiopathic interstitial pneumonias, a common morphologic response to a different set of insults, remains to be determined. Nonetheless, the findings in our patients suggest that in many instances this particular lesion is associated with a poor prognosis.

REFERENCES

1. American Thoracic Society/European Respiratory Society International Multidisciplinary Consensus. Classification of the idiopathic interstitial pneumonias. *Am J Respir Crit Care Med*. 2002;165:277–304.
2. De Carvalho PEP, Kairalla RA, Capelozzi VL, et al. Centrilobular fibrosis: a novel histological pattern of idiopathic interstitial pneumonia. *Pathol Res Pract*. 2002;198:577–583.
3. Fulmer JD, Roberts WC, von Gal ER, et al. Small airways in idiopathic pulmonary fibrosis: comparison of morphologic and physiologic observations. *J Clin Invest*. 1977;60:595–610.
4. Glazer CS, Rose CS, Lynch DA. Clinical and radiologic manifestations of hypersensitivity pneumonitis. *J Thorac Imaging*. 2002;17:261–272.
5. Katzenstein AL, Myers JL. Idiopathic pulmonary fibrosis: clinical relevance of pathologic classification. *Am J Respir Crit Care Med*. 1998; 157:1301–1315.
6. King TE, Mortenson RL. Syndromes that mimic idiopathic pulmonary fibrosis. *Immunol Allergy Clin North Am*. 1992;12:461–489.
7. Kraft M, Mortenson RL, Colby TV, et al. Cryptogenic constrictive bronchiolitis: a clinicopathologic study. *Am Rev Respir Dis*. 1993;148:1093–1101.
8. Markopoulou KD, Cool CD, Elliot TL, et al. Obliterative bronchiolitis: varying presentations and clinicopathological correlation. *Eur Respir J*. 2002;19:20–30.
9. Miller A, Teirstein AS, Jackler I, et al. Airway function in chronic pulmonary sarcoidosis with fibrosis. *Am Rev Respir Dis*. 1974;109:179–189.
10. Myers JL, Veal CF, Shin MS, et al. Respiratory bronchiolitis causing interstitial lung disease: a clinicopathologic study of six cases. *Am Rev Respir Dis*. 1987;135:880–884.
11. Pérez-Padilla R, Gaxiola M, Salas J, et al. Bronchiolitis in chronic pigeon breeder's disease: morphological evidence of a spectrum of small airway lesions in hypersensitivity pneumonitis induced by avian antigens. *Chest*. 1996;110:371–377.
12. Pérez-Padilla R, Regalado J, Vedal S, et al. Exposure to biomass smoke and chronic airways in Mexican women: a case control study. *Am J Respir Crit Care Med*. 1996;154:701–706.
13. Selman M. Hypersensitivity pneumonitis. In: Schwarz M, King T, eds. *Interstitial Lung Disease*, Hamilton, Ontario: B.C. Decker, 1998:393–422.
14. Shaw RJ, Djukanovic R, Tashkin DP, et al. The role of small airways in lung disease. *Respir Med*. 2002;96:67–80.
15. Travis WD, Matsui K, Moss J, et al. Idiopathic nonspecific interstitial pneumonia: prognostic significance of cellular and fibrosing patterns: survival comparison with usual interstitial pneumonia and desquamative interstitial pneumonia. *Am J Surg Pathol*. 2000;24:19–33.
16. Travis WD, Colby TV, Koss MN, et al. *Non-neoplastic Disorders of the Respiratory Tract*. Washington DC: American Registry of Pathology, 2002:361–362.
17. Yousem SA, Dacic S. Idiopathic bronchiolocentric interstitial pneumonia. *Mod Pathol*. 2002;15:1148–1153.

© 2003 Lippincott Williams & Wilkins

Copyright © Lippincott Williams & Wilkins. Unauthorized reproduction of this article is prohibited.